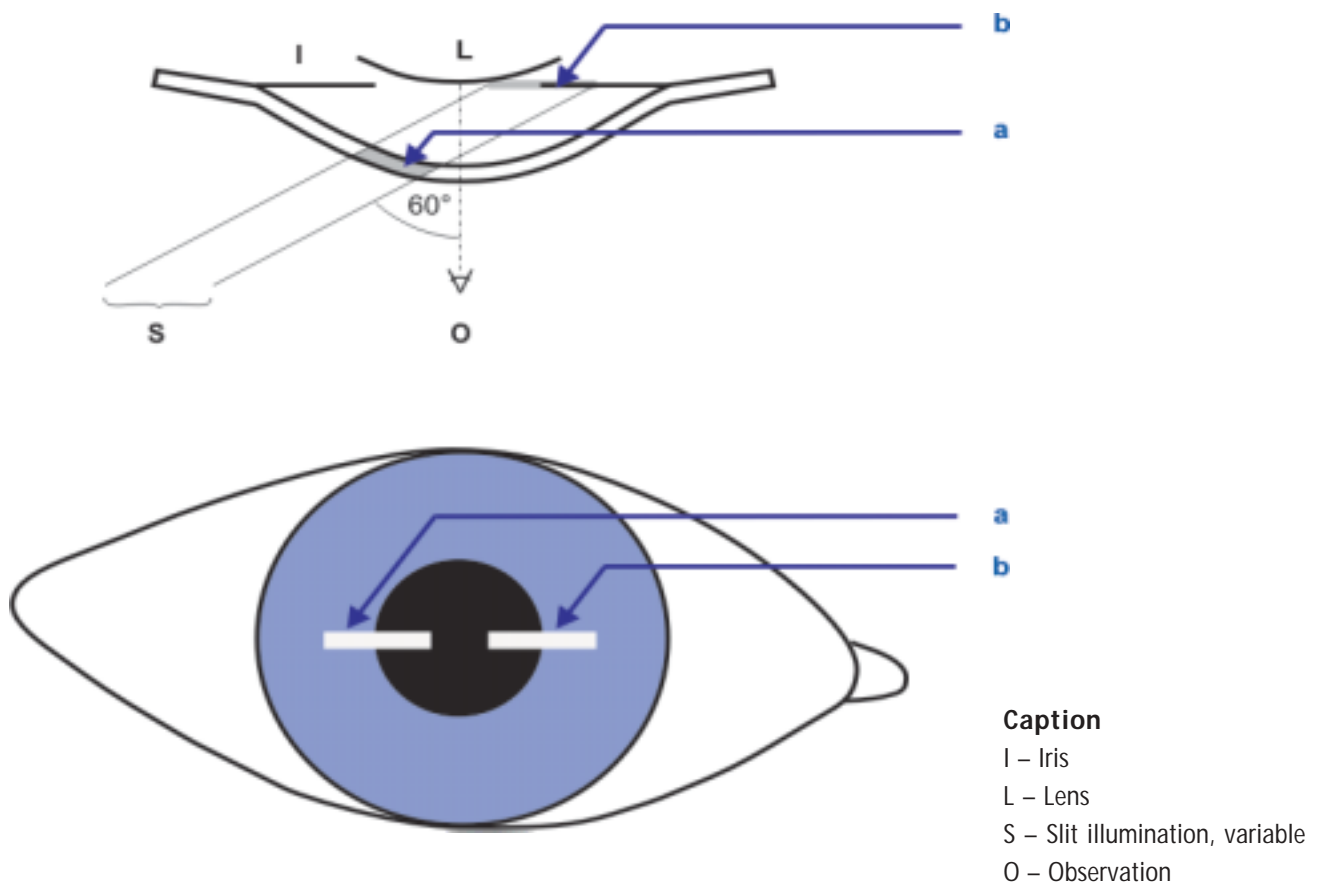


## Determination of Central Anterior Chamber Depth with Zeiss SL 120 and SL 130 Slit Lamps

The method for the determination of the anterior chamber depth described by Smith is based on the projection of a horizontal light slit onto the patient's eye. The two slit images produced on cornea and iris/lens are brought to a defined coincidence by varying the slit length. The central anterior chamber depth can be determined by means of the slit length in coincidence position. The method according to Smith does not require the use of any additional slit lamp accessories.

The estimations obtained with this method provide accurate and reproducible results; moreover, it can be performed quickly and easily on the slit lamp. Therefore, the method according to Smith represents a good option for the alternative assessment of the anterior chamber, if the instruments needed for the exact measurement of the anterior chamber depth are not available.



**Fig. 1**

### ***Schematic diagram of the method according to Smith - Starting position***

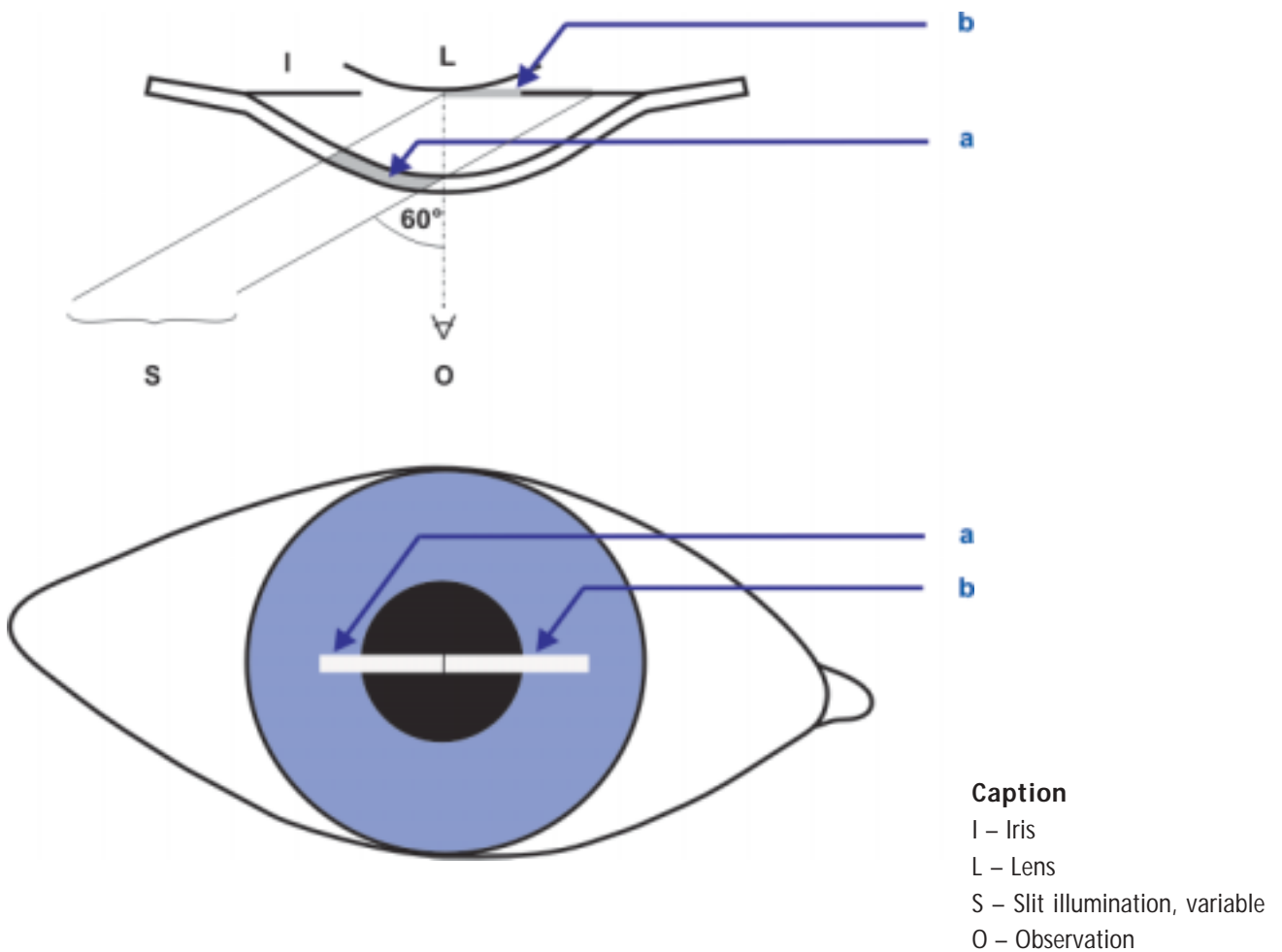
*Between the slit images on the cornea (a) and on the lens/ iris (b) a dark region is visible. The slit length has to be increased until both slit images just seem to touch.*

### Instrument adjustments

Set the slit image horizontally by rotating the slit by  $90^\circ$ . Choose an angle of  $60^\circ$  between slit illumination and microscope and fix this setting. The microscope is in mid-position and slit illumination should be temporal. Have the patient look straight ahead; a fixation target can be used on the non-examined eye, if necessary.

Having set a slit length of 1 – 2 mm, focus the slit on the cornea. Now, you can observe the following image: The slit image is first incident on the epithelium of the cornea, then it transmits the stroma (a, Fig. 1).

This is followed by an optically empty region before the slit is incident on the anterior surface of the lens and the iris (b, Fig. 1). The obtained slit image is slightly unsharp. If you incrementally increase the slit length, the optically empty region becomes smaller and smaller. When the slit on the endothelial side of the cornea and the slit on the anterior lens surface just seem to touch (a and b, Fig. 2), measure the actual slit length by reading the scale of the slit projector or by using a micrometer eyepiece. The slit length multiplied by a factor of 1.4 gives the central anterior chamber depth in mm.

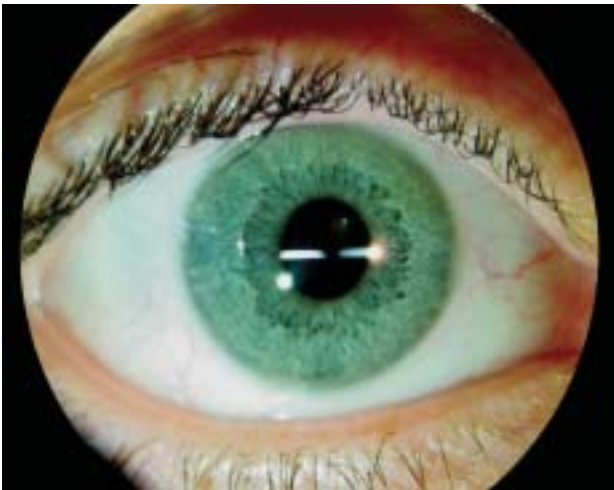


**Fig.2**

*Schematic diagram of the method according to Smith - Coincidence position*

*In the field of view of the examiner, the slit images on the cornea (a) and on the lens/ iris (b) just seem to touch. In this coincidence position, the slit length is measured.*

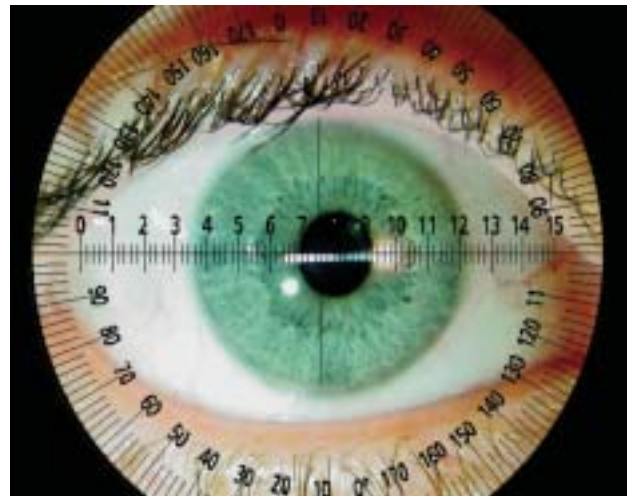
When adjusting the slit length, you should ensure that when examining the right eye you only use the right eyepiece and vice versa. When applying the described method, the slit width is of minor importance. It should be adjusted wide enough to allow the slit image to be seen sufficiently well. When you use the micrometer eyepiece for determining the slit length, make sure to set a magnification of 8x, as only with this magnification stage you can read the measured values on a scale of 1:1.



**Fig. 3**

**Measurement of central anterior chamber depth**

The two slit images on cornea and iris or lens are visible. Between both images, a dark region can be seen, in which the slit is falling through the anterior chamber. To reach the measuring position, it is necessary to increase the slit length (see Fig. 4).



**Fig. 4**

**Measurement of central anterior chamber depth, measuring position**

It can be seen that the two slit images on cornea and iris or lens just unite to form a single line. In this setting, the slit length can be read to determine the anterior chamber depth. In the selected example, the slit length is 1.8 mm. From this value, the anterior chamber depth is calculated:

$1.8 \text{ mm} \cdot 1.4 = 2.52 \text{ mm}$ . For comparison, the anterior chamber depth of the same test person was measured with the Zeiss IOLMaster™. The measurement resulted in a value of 3.06 mm. Please note that the measurements with the Zeiss IOLMaster™ include the thickness of the cornea. Subtracting the typical corneal thickness (about 0.56 mm) from this value makes the results of both measuring techniques comparable. Thus, the measurement with the IOLMaster™ results in an anatomical anterior chamber depth of 2.50 mm. The value of 2.52 mm found by the Smith method very well compares with this value.

Note: As it is not possible to photograph through the micrometer eyepiece, the scale of the micrometer eyepiece was inserted later in the image for illustration.

## Authors

Robert Wilke, qualified physician; robert\_wilke\_999@hotmail.com  
Burkhard Wagner, product manager; b.wagner@meditec.zeiss.com

## References

1. Barrett BT, McGraw PV, Murray LA, Murgatroyd P: Anterior chamber depth measurement in clinical practice. *Optometry and Vision Science* 1996; 73: 482-486
2. Douthwaite WA, Spence D: Slit-lamp measurement of the anterior chamber depth. *British Journal of Ophthalmology* 1986; 70: 205-208
3. Jacobs ICH: Anterior chamber depth measurement using the slit lamp microscope. *American Journal of Ophthalmology* 1979; 88: 236-238
4. Osuobeni EP, Oduwaiye KA, Ogbuehi KC: Intra-observer repeatability and inter-observer agreement of the Smith method of measuring the anterior chamber depth. *Ophthalmic and Physiological Optics* 2000; 20:153-159
5. Osuobeni EP, Oduwaiye KA: The Effect of Illumination-Microscope Angle on Slit Lamp Estimate of the Anterior Chamber Depth. *Optometry and Vision Science* 2003; 80: 237-244
6. Smith RJH: A new method of estimating the depth of the anterior chamber. *British Journal of Ophthalmology* 1979; 63: 215-220