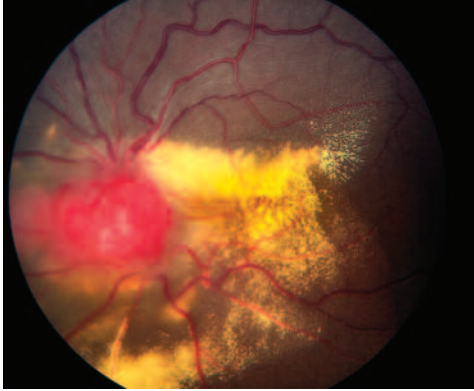
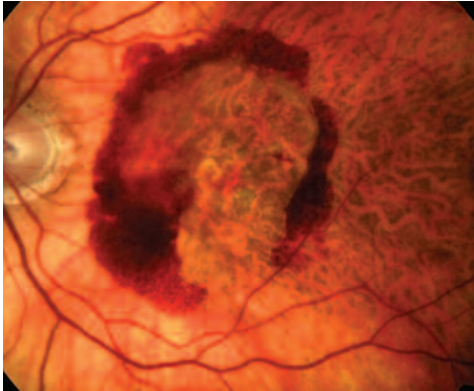


Clinical Image Gallery

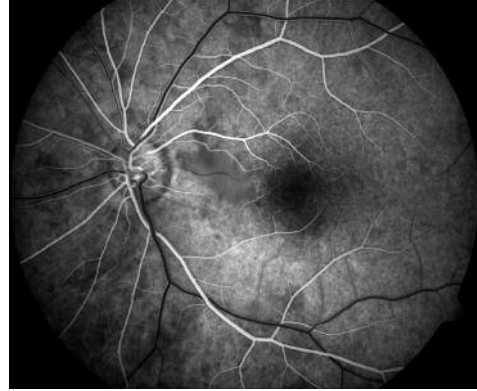COR.1302
© 2007 Carl Zeiss Meditec, Inc. All rights reserved. Specifications subject to change. Printed in the USA. 0307 32M



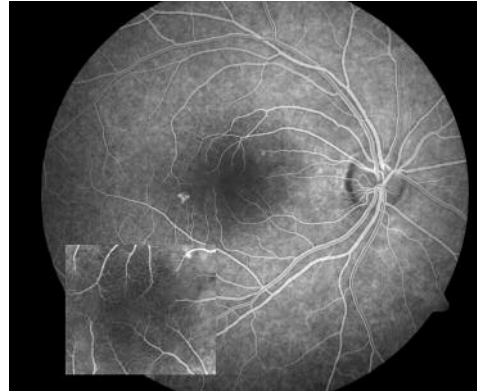
"Tumor" by Allan Connor, Ocular Oncology, Princess Margaret Hospital, University Health Network, Toronto, Ontario, Canada. Photographed with the ZEISS FF 450^{plus} Fundus Camera and VISUPAC Digital Imaging and Archive Management System.



"Age-Related Macular Degeneration" by Fred Hanamoto, Bay Area Retina Associates, Walnut Creek, California. Photographed with the VISUCAM^{PRO NM} Non-Mydriatic Fundus Camera.



"Cilioretinal Artery" by Gene Saldana, Loma Linda University Health Care Center, Loma Linda, California. Photographed with the ZEISS FF 450^{plus} Fundus Camera and VISUPAC Digital Imaging and Archive Management System.



"CSR" by Hoang Nguyen, CRA, Retinal Alliance, PC, Denver, Colorado. Photographed with the ZEISS FF 450^{plus} Fundus Camera and VISUPAC Digital Imaging and Archive Management System.



Carl Zeiss Meditec, Inc.

5160 Hacienda Drive
Dublin, CA 94568
USA

PRSRST STD

U.S. Postage

PAID

Permit #688

Redwood City, CA