

Presented by: Brian Kim, M.D. and Neil M. Bressler, M.D., the Retina Division, Wilmer Eye Institute, Department of Ophthalmology, the Johns Hopkins University School of Medicine, Baltimore.

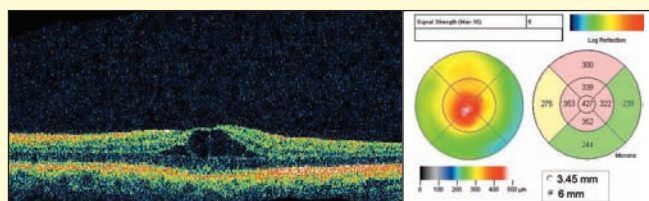
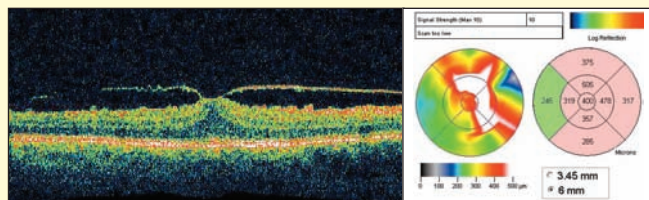
# Using Stratus OCT to Understand Decreased Vision Associated with Retinal Thickening in the Macula Following Cataract Surgery

## The patient

A 71-year-old man presented with complaints of gradually decreasing vision in both eyes several months after cataract surgery in each eye. Visual acuity was 20/32 in his right eye and 20/40 in his left eye. Slit lamp biomicroscopy with contact lens was performed and revealed retinal thickening in the macula of both eyes.

## The Stratus OCT diagnosis

Optical coherence tomography (OCT) was obtained to clarify the characteristics of the retinal thickening in each eye. Stratus OCT documented the presence of retinal edema associated with vitreomacular traction in the right eye (top), and cystic edema presumably from post-surgical cystoid macular edema (CME) in the left eye (bottom).



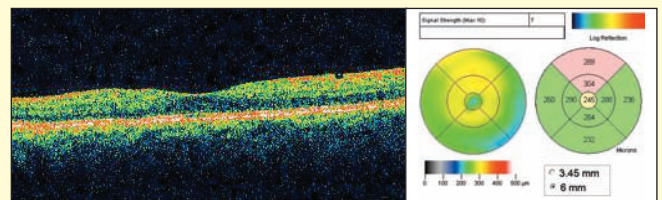
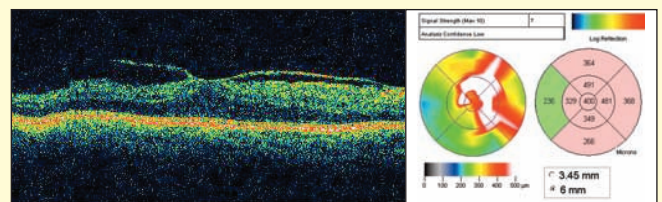
Treatment with ketorolac tromethamine (Acular) eye drops was initiated in the left eye, but treatment also was initiated in the right eye in case any of the retinal thickening in that eye had a component of post-surgical CME. The expectation was only the left eye likely would benefit from the drops.

## The surgical outcome

The patient was seen 2 months later with improvement in symptoms and vision. Visual acuity was 20/25

in his right eye and 20/20 in his left eye. Slit lamp biomicroscopy with contact lens revealed improvement in his left eye but no change in his right eye. Results were confirmed with Stratus OCT imaging.

As expected, Stratus OCT of the right eye (top) revealed no improvement with ketorolac eye drops so they were discontinued. Stratus OCT of the left eye (bottom) revealed marked improvement associated with ketorolac eye drops.



## Discussion

This case demonstrates the utility of the Stratus OCT to evaluate decreased vision accompanied by retinal thickening after cataract surgery. In this case, the Stratus OCT revealed two different causes of retinal thickening, which could not be discriminated easily on biomicroscopic examination. This finding affected patient management. In the right eye, the cause appeared to be vitreomacular traction, which likely would not respond to ketorolac, and indeed no response was seen. In the left eye, postsurgical CME was noted.

**Note:** The authors have no financial interest in this material. Johns Hopkins University, but not Dr. Bressler, receives funding from Carl Zeiss Meditec for research efforts by Dr. Bressler on behalf of the Department of Ophthalmology.