

By Greg Haffner, M.D., New England Retina Associates, Hamden, Conn. and George Shafranov, M.D., L.L.C., Glaucoma Surgery and Consultations, Guilford, Conn.

Resolution of Pseudophakic Cystoid Macular Edema with Topical Nonsteroidal Prostaglandin Inhibitors

The patient

A 51-year-old woman underwent uneventful cataract surgery of her left eye with phacoemulsification and posterior chamber implant. Her past ocular history was significant for chronic angle-closure glaucoma in both eyes, for which she had undergone laser iridectomies. At the time of surgery, she was on dorzolamide/timolol maleate (Cosopt) b.i.d. in each eye and brimonidine (Alphagan) t.i.d. in each eye. Postoperative day 1, the patient's visual acuity was 20/25 and was on prednisolone acetate 1% (Pred Forte) 6x day and dorzolamide/timolol maleate b.i.d. in the left eye.

The Stratus OCT diagnosis

One month post-op the patient's vision had worsened to 20/60 after a slow steroids taper.

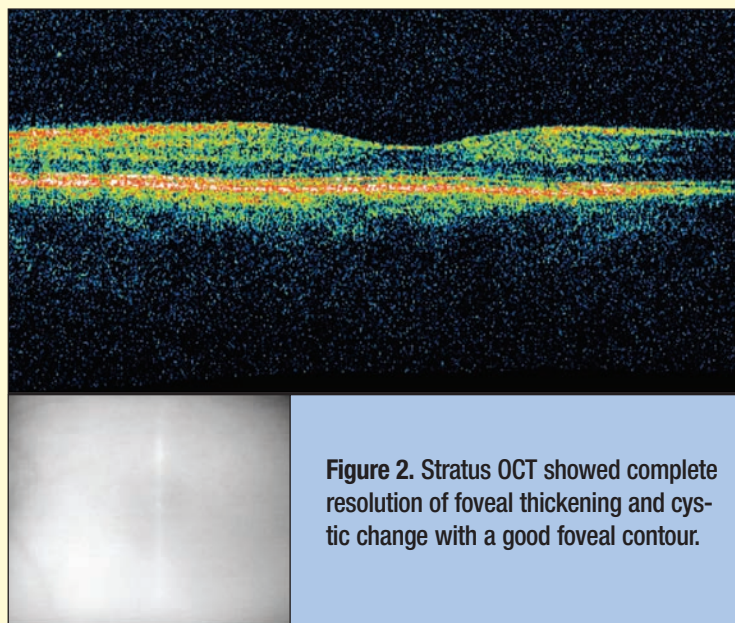


Figure 2. Stratus OCT showed complete resolution of foveal thickening and cystic change with a good foveal contour.

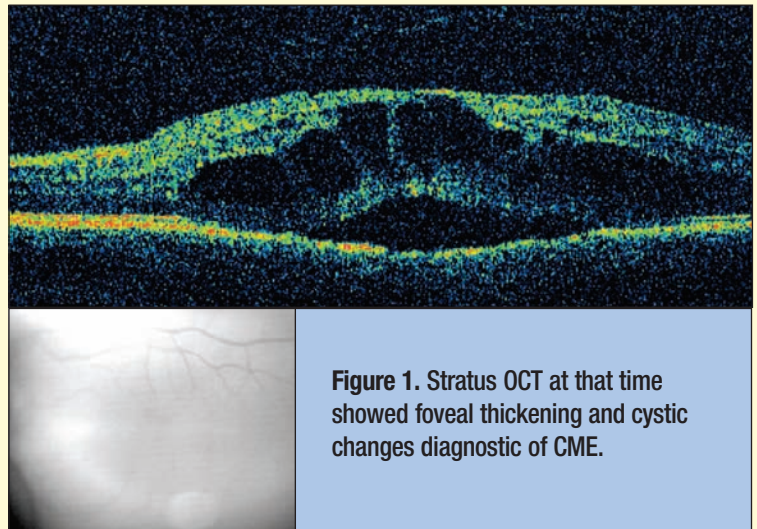


Figure 1. Stratus OCT at that time showed foveal thickening and cystic changes diagnostic of CME.

At that time, Stratus OCT was the vital tool in proper diagnosis and subsequent treatment of this condition. The Stratus OCT showed foveal thickening and cystic changes diagnostic of cystoid macular edema (Figure 1). The patient was placed on a topical non-steroidal anti-inflammatory drug (NSAID), ketorolac tromethamine 0.5 % (Acular) q.i.d. in the left eye. At the patient's 4-month follow-up visit, vision had improved to 20/20, and the fovea appeared flat. Repeat Stratus OCT showed complete resolution of foveal thickening and cystic change with a good foveal contour (Figure 2).

Outcome

Our case describes a case of pseudophakic CME which resolved completely after topical NSAID therapy 4 months later, as documented by Stratus OCT. Only with the Stratus OCT could this pathology be visualized.

Note: The authors have no financial interest in this material.