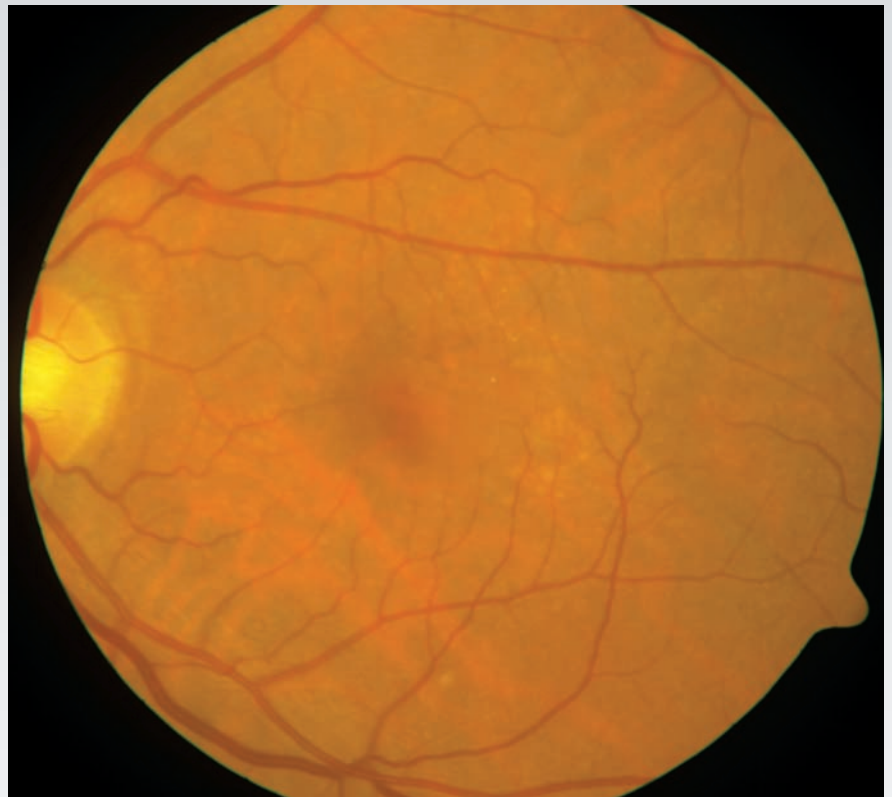
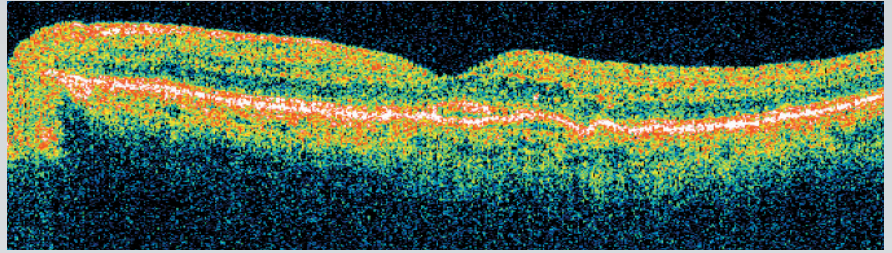


Stratus OCT

Provided by Gregory C. Hoffmeyer, Sr. Technical Analyst, The OCT Reading Center at Duke, Manager of Research Imaging, Duke Eye Imaging, Duke University, Durham, North Carolina, USA

This is a textbook case of dry, or non-neovascular age-related macular degeneration (AMD) on the verge of turning wet, or neovascular. Drusen and exudates can be seen on the fundus photo and in the Stratus OCT scan. On the Stratus OCT scan, RPE modulations with no optical shadowing are consistent with soft drusen.



Images Courtesy of Gregory C. Hoffmeyer

Images acquired using the Stratus OCT and FF 450^{plus} Fundus Camera with the VISUPAC 481XR Digital Imaging and Archive Management system