

The Dental Microscope: An Indispensable Tool in Endodontic Practice

Thomas Clauder, DMD

High-quality endodontic therapy is the basis for long-term function and biologic success, ensuring that patients remain free of pain. State-of-the-art equipment and thorough clinical know-how are vitally important to reach this goal. Today, the world's leading practicing dentists and researchers are largely in agreement that in endodontics the dental microscope has pushed the limits of treatment potential a long way towards enhancing long-term patient outcomes.

Nowadays, teeth that require endodontic therapy can provide a basis for many aesthetically demanding prosthetic restorations. Routine endodontic practice, however, confronts the practitioner with an increasing number of challenges (Fig. 1).

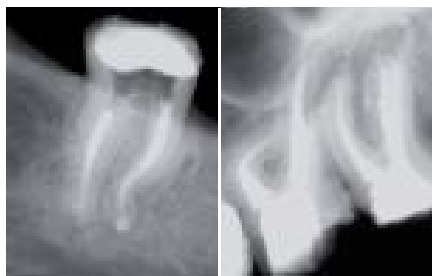

Fig. 1: X-ray images of S-shaped and crooked root canals

For example, anatomical variations are not as rare or exotic as is frequently assumed and can in themselves form the basis for disease. Walter Hess described the complex anatomy of root canals in great detail as early as 1917.⁴ Subsequent anatomical studies have since been published in various countries and a broad range of populations. Many of these important structures cannot be readily detected or treated with traditional endodontic treatment methods. Failures in non-surgical and surgical endodontic therapy were frequent, and they still are. This is reflected in daily

dental practice and cross-sectional epidemiological studies. The discrepancy between possible successful prognosis and reality is quite substantial.

The introduction of the dental microscope and the associated ability to inspect the root canals – both orthograde and retrograde – have fundamentally changed our understanding of dental morphology and its complexity.

However, following the first publications there was no widespread acceptance of microscopic techniques among dentists, until the beginning of the 1990s. Well-known specialists such as Prof. Syngcuk Kim (University of Pennsylvania, Philadelphia, USA) and Dr. Gary Carr (San Diego, USA) facilitated the establishment and widespread use of microscopic techniques. Prof. Kim's motto "You can only treat what you can see!" has made dentists all over the world enthusiastic about microscopic treatment. In 1998, the American Dental Association instituted microscope proficiency as obligatory for all endodontic specialist programs in the USA.

As the use of dental microscopes increased worldwide, new instruments became established, the utilization of which greatly facilitates a considerable amount of work under the microscope. For a restorative dentist or endodontic specialist, the dental microscope offers

a large number of benefits:

1. Better visualization.

Due to the magnification, and clear coaxial illumination of the working field, it is possible to address unique or specialized treatment situations more efficiently and with greater precision.

2. Improved treatment quality.

Microscopic techniques are superior to traditional treatment concepts, as has been proven by various studies.^{1,7,8,10}

3. Ideal treatment ergonomics.

Appropriate working posture and ergonomics play a key role in maintaining the dentist's own health and personal well-being. For some colleagues, this is the main criterion for daily use in their practice (Fig. 2).

4. "Fun factor" in the practice.

Clinicians that utilize a dental microscope will find they have more enjoyment during procedures due to the ideal working conditions and the predictable treatment outcomes. They will be more motivated as treatment is experienced more intensely and visualization is improved considerably. Dentists, assisted by illumination, magnification, and special instruments, will also gradually experience a greater level of personal satisfaction. This is driven by their ability to recognize much greater detail, visualize many more root

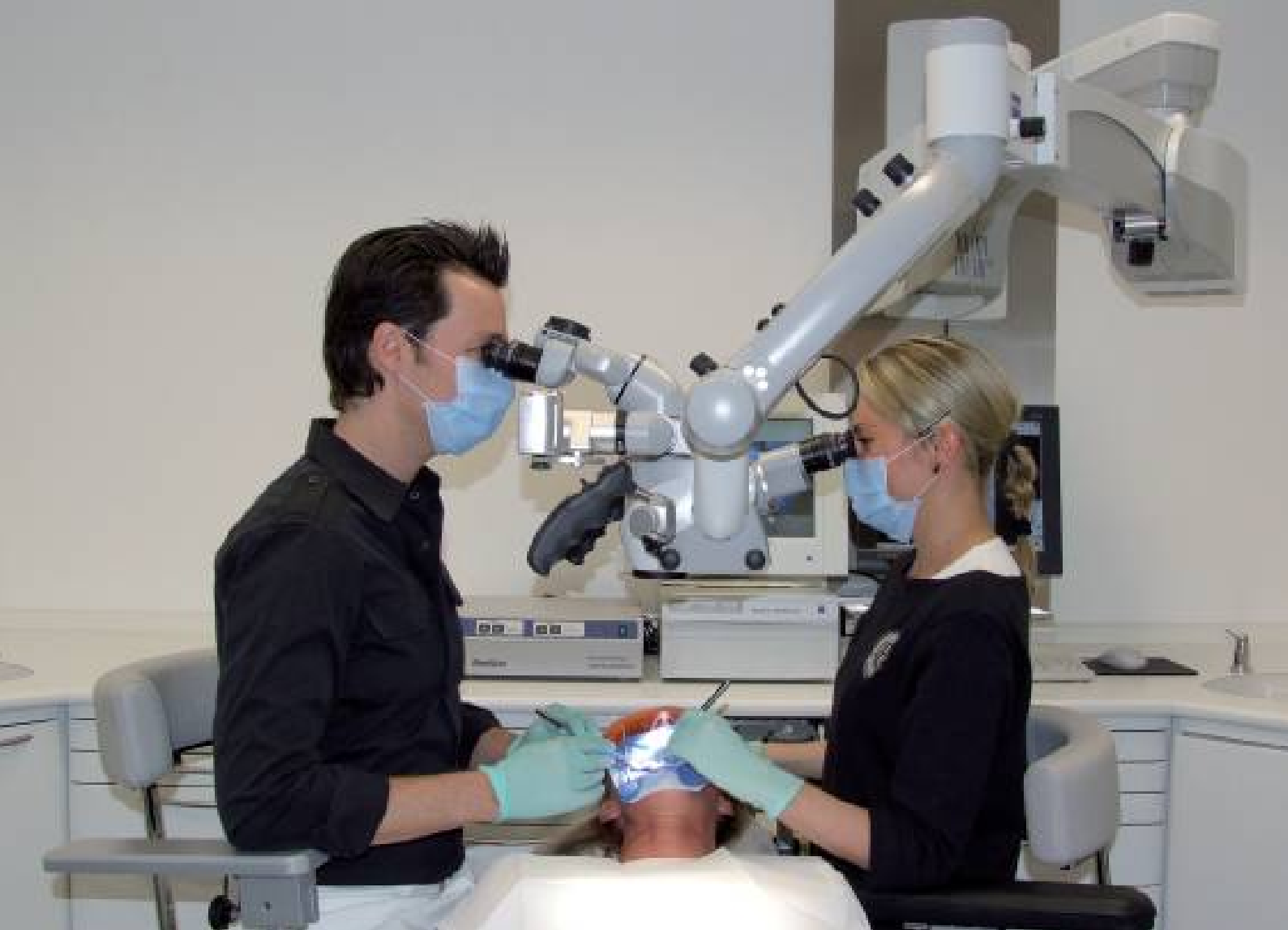

Fig. 2: Dr. Thomas Clauder and Dr. Caroline Neumann working with OPMI® PROergo equipped with a co-observation tube

canals and anomalies, treat them successfully, and ultimately achieve more therapy successes, particularly those with spectacular results. The dentist can explain this to the patient and, through enthusiasm and fascination, enable him or her to participate in this positive effect.

In all areas, from exposure of the access cavity and preparation to three-dimensional obturation and postendodontic management, the microscope provides major advantages over working without appropriate magnification. As a result, the use of the microscope can be expressly recommended for the following specific indications and special aspects:

1. Diagnosis.

Microfractures and longitudinal fractures are often overlooked clinically and represent a cause of pain that is difficult to diagnose (Figs. 3, 4). Visualization

under the dental microscope is the basis for further treatment planning.

2. Canals/canal systems that are difficult to localize.

If the radiographic image is examined more closely, there are often signs of unusual root and/or canal shapes like those caused by changes in the course of canal anatomy or root surface. Interruptions in the canal shape are almost always a certain indication of canal system splitting. An off-center exposure or three dimensional image can provide further valuable information. Three-rooted premolars, for example, are encountered in six percent of all first maxillary premolars (Figs. 5, 6).² However, anatomical variations also include other complex structures like C-shaped canals. In the case of second mandibular molars, they account for approximately 7.6%. However, in Asian

populations such as in Koreans they can reach up to 31.3% (Figs. 7, 8).^{5,9,12} Treatment of this anatomical variation can be highly complex. Without a doubt, the second mesiobuccal canal in maxillary molars, which is often difficult to localize and prepare, is the reason why the failure rate is highest in first maxillary molars (Fig. 9). Depending on the literature source, the frequency of the fourth canal is determined to be between 52% and 95.2% in vitro and between 16% and 78% in vivo.³ Virtually all studies point to distinct advantages in the localization of second mesiobuccal canals when using a dental microscope.

3. Obliterations and calcifications.

These signs occur to a greater or lesser extent in 50% of all teeth, impairing instrumentation considerably or essentially preventing treatment of the canal system (Fig. 10).

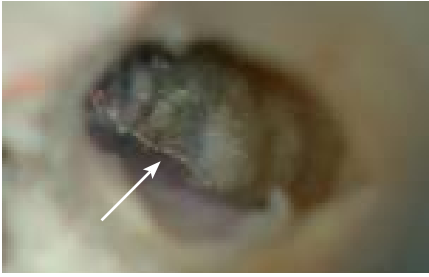

Fig. 3: Microfracture diagnosed during orthograde root canal treatment

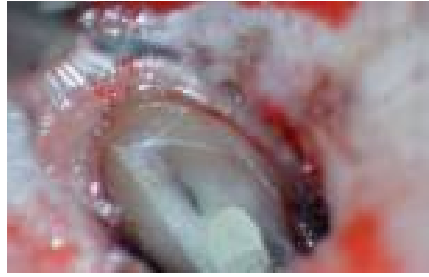

Fig. 4: Microfracture diagnosed during microsurgical endodontic treatment

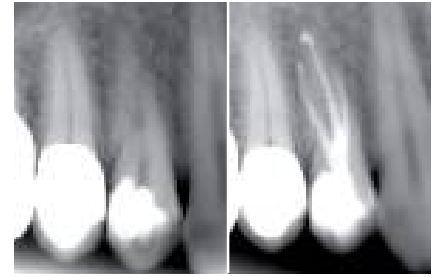

Fig. 5: X-ray images of a three-rooted premolar (pre- and postoperative)

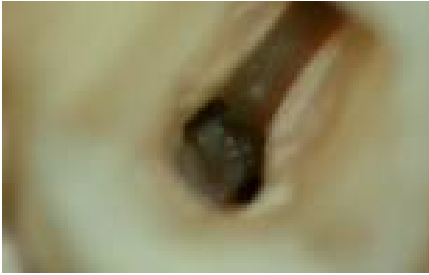

Fig. 6: Buccal separation of a three-rooted premolar

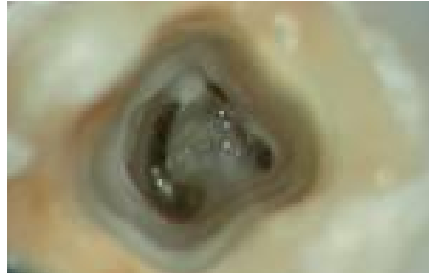

Fig. 7: Excavation of a C-shaped root canal

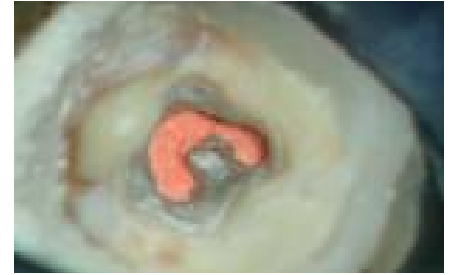

Fig. 8: Obturation of a C-shaped root canal

4. Denticles.

This specific form of calcification is also encountered very frequently. Denticles can be found even on the molars of young patients in 19.7% of cases.⁶ They can block the canal entrance or even obstruct further instrumentation (Fig. 11).

5. Open apex.

Modern apexification therapies call for special treatment techniques and materials, the manipulation of which is facilitated significantly under a dental microscope (Figs. 12-14).

6. Perforation repair and removal of fractured instruments.

Treatment of these iatrogenic problems

and treatment prognosis chiefly involve visualization of the problem so the microscope certainly plays a major role in this context. If, for example, the fragment can be removed without any major loss of tooth structure, the prognosis for preservation of the tooth is quite good (Figs. 15, 16).

7. Microsurgical apicoectomy.

Modern techniques involve: microsurgical flap design and suture techniques, atraumatic procedures during resection, management of the bone structures, minimally invasive retrograde cavity preparation and retrograde filling of the canal system and all its branches. Modern microsurgical concepts were published

by Prof. Kim in the 1990s. They provide not only an atraumatic procedure and fewer complications for patients, but also a much better prognosis than traditional procedures (Fig. 17). While conventional apicoectomies can expect prognoses with a success rate of around 60%, the prognosis for a microsurgical procedure is significantly better.

A very convincing study concerning the benefits of microsurgical procedures was reported by Rubinstein and Kim in 1999.^{7,8} While the short-term investigation confirmed healing in 96.8% of cases⁷, the follow-up after 5-7 years also attains an amazingly good healing success rate of 91.5%.⁸ This is well

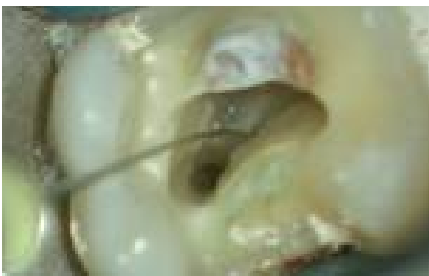

Fig. 9: Localization of the second mesio-buccal canal (MB II) of an upper first molar

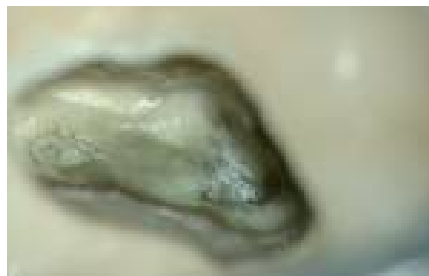


Fig. 10: Obliterated canal orifices impair instrumentation or even prevent root canal treatment

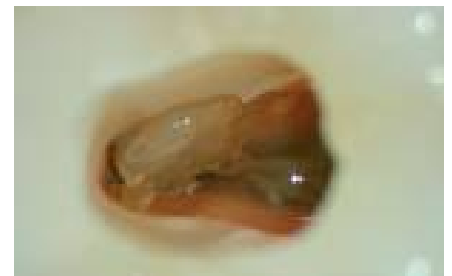


Fig. 11: Denticles may block the canal entrance

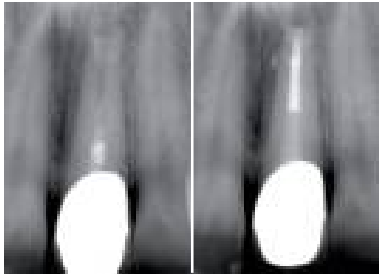


Fig. 12: X-ray images of the treatment of an open apex

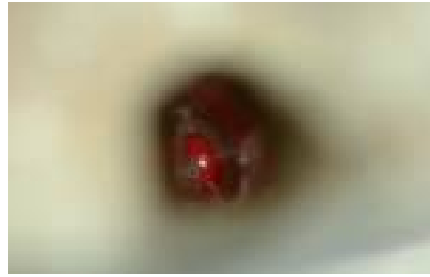

Fig. 13: Localization of the root canal end




Fig. 14: Creation of a barrier across the open apex, before obturation

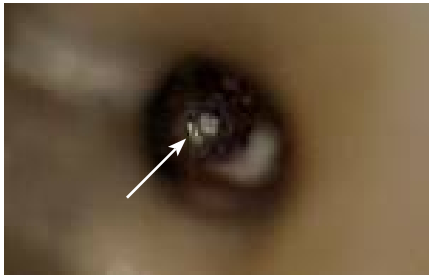


Fig. 15: Visualization of a fractured instrument is essential for retrieval

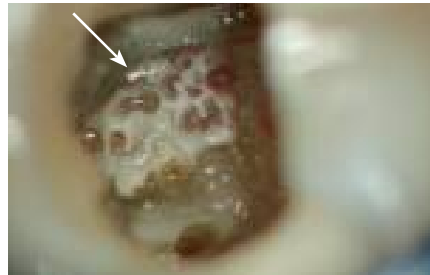

Fig. 16: Cleaned out perforation site and visible bone in the furcation

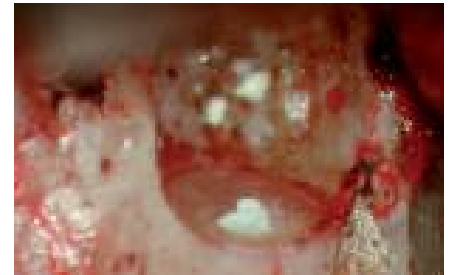

Fig. 17: Microsurgical retropreparation and retrofill with mineral trioxide aggregate (MTA)

beyond the success rates of conventional apicoectomy procedures. Another study points to an even greater discrepancy of 44.2% for the traditional method and 91.1% for microsurgical techniques.¹¹

The dental microscope not only offers many useful applications in the treatment of root canals and throughout the entire field of dentistry, but also improves the overall treatment quality. It encourages dentists to review and perfect their own treatment concepts resulting in a positive impact on the entire practice structure.

Image courtesy: Dr. Thomas Clauder, Hamburg, Germany

References:

- Baldassari-Cruz L. A., Lilly J. P., Rivera E. M. (1998): Effectiveness of mesiolingual canal location with and without the use of the microscope. *J Endod* 1998; 24: 287 (abstract OR 63)
- Carns E. J., Skidmore A. E. (1973): Configurations and deviations of root canals of maxillary first premolars. *Oral Surg Oral Med Oral Pathol* 1973; 36: 880-886
- Görduysus M. Ö., Görduysus M., Friedman S. (2001): Operating microscope improves negotiation of second mesiobuccal canals in maxillary molars. *J Endod* 2001; 27: 683-686
- Hess W. (1917): Zur Anatomie der Wurzelkanäle des menschlichen Gebisses mit Berücksichtigung der feineren Verzweigungen am Foramen apicale. *Schweiz Vierteljahrsschr Zahnheilk* 1917; 27: 1-34
- Jafarzadeh H., Wu Y.-N. (2007): The C-shaped Root Canal Configuration: A Review. *J Endod* 2007; 33(5): 517-523
- Ranjitkar S., Taylor J. A., Townsend G. C. (2002): A radiographic assessment of the prevalence of pulp stones in Australians. *Aust Dent J* 47, 36-40
- Rubinstein R. A., Kim S. (1999): Short-term observation of the results of endodontic surgery with the use of a surgical operating microscope and Super-EBA as root-end filling material. *J Endod* 1999; 25: 43-48
- Rubinstein R. A., Kim S. (2002): Long-term follow-up of cases considered healed one year after apical microsurgery. *J Endod* 2002; 28: 378-383
- Seo M. S., Park D. S. (2004): C-shaped root canals of mandibular second molars in a Korean population: clinical observation and in vitro analysis. *Int Endod J* 2004; 37: 139-144
- Stropko J. J. (1999): Canal morphology of maxillary molars: clinical observations of canal configurations. *J Endod* 1999; 25: 446-450
- Tsesis I., Rosen E., Schwartz-Arad D., Fuss Z. (2006): Retrospective Evaluation of Surgical Endodontic Treatment: Traditional versus Modern Technique. *J Endod* 2006; 32(5): 412-416
- Weine F. S. (1998): The C-shaped mandibular second molar: Incidence and other considerations. *J Endod* 1998; 24: 372-375



Dr. Thomas Clauder is a graduate of the University of Hamburg, Germany. He has been working in a joint dental office in Hamburg since 1997 and has used a dental microscope since that time. After completing the International Program and obtaining his certification as a specialist from the University of Pennsylvania, USA, Department of Endodontics, he devoted his attention solely to endodontics and endodontic microsurgery. Dr. Clauder is a Certified Member of the European Society of Endodontology (ESE) and member of the American Association of Endodontists (AAE). He is also a charter member and former Vice President of the German Endodontics Association (DGEndo). Dr. Clauder can be reached at Thomas.Clauder@praxis-clauder.de | www.praxis-clauder.de