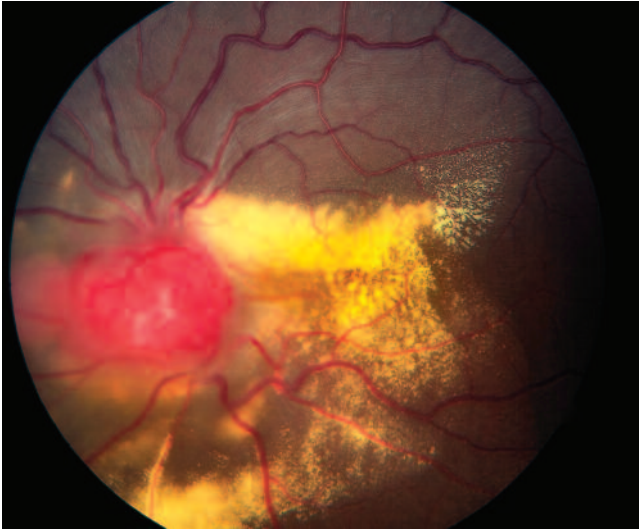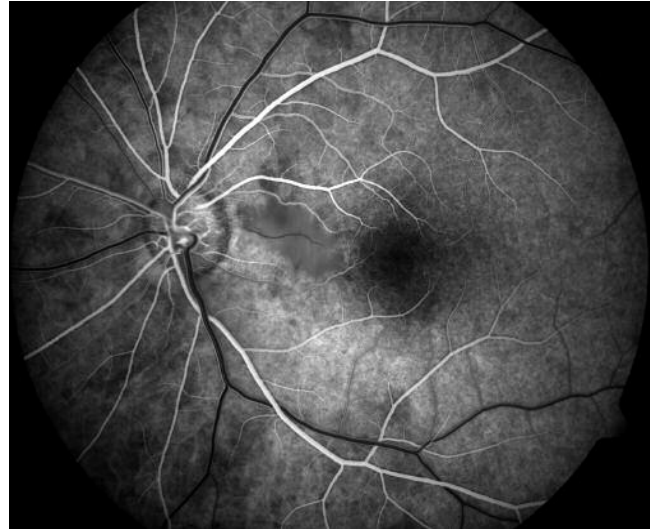


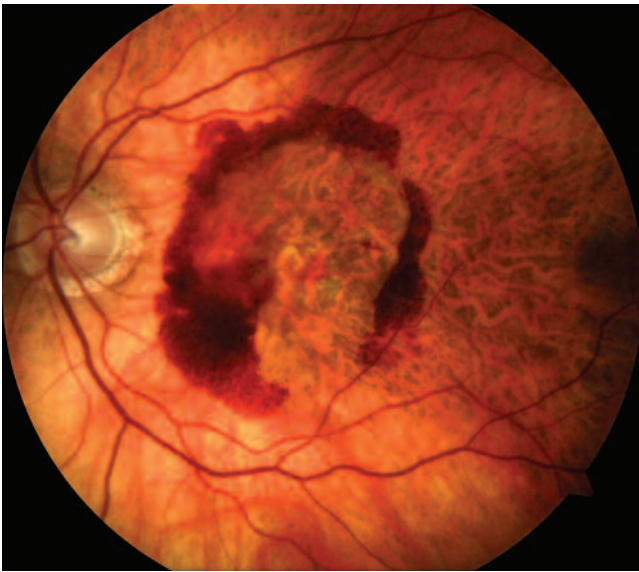## Clinical Image Gallery



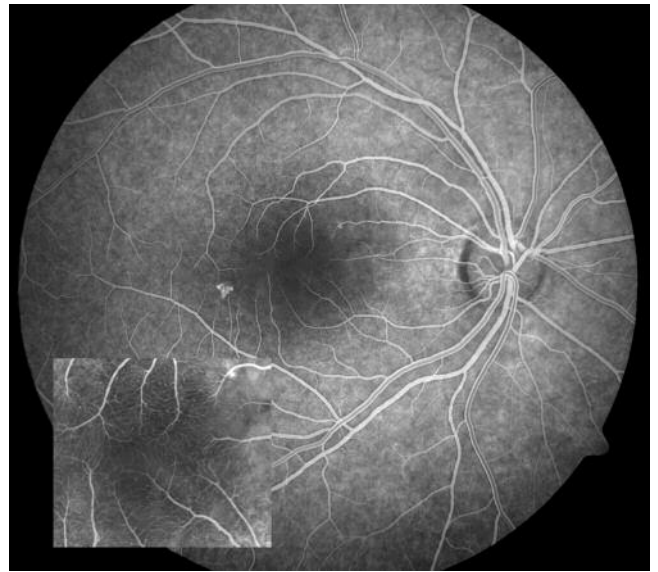
*"Tumor" by Allan Connor, Ocular Oncology, Princess Margaret Hospital, University Health Network, Toronto, Ontario, Canada. Photographed with the ZEISS FF 450<sup>plus</sup> Fundus Camera and VISUPAC Digital Imaging and Archive Management System.*



*"Cilioretinal Artery" by Gene Saldana, Loma Linda University Health Care Center, Loma Linda, California. Photographed with the ZEISS FF 450<sup>plus</sup> Fundus Camera and VISUPAC Digital Imaging and Archive Management System.*



*"Age-Related Macular Degeneration" by Fred Hanamoto, Bay Area Retina Associates, Walnut Creek, California. Photographed with the VISUCAM<sup>PRO NM</sup> Non-Mydriatic Fundus Camera.*



*"CSR" by Hoang Nguyen, CRA, Retinal Alliance, PC, Denver, Colorado. Photographed with the ZEISS FF 450<sup>plus</sup> Fundus Camera and VISUPAC Digital Imaging and Archive Management System.*