

**Cirrus™ HD-OCT:
How to read the printouts**



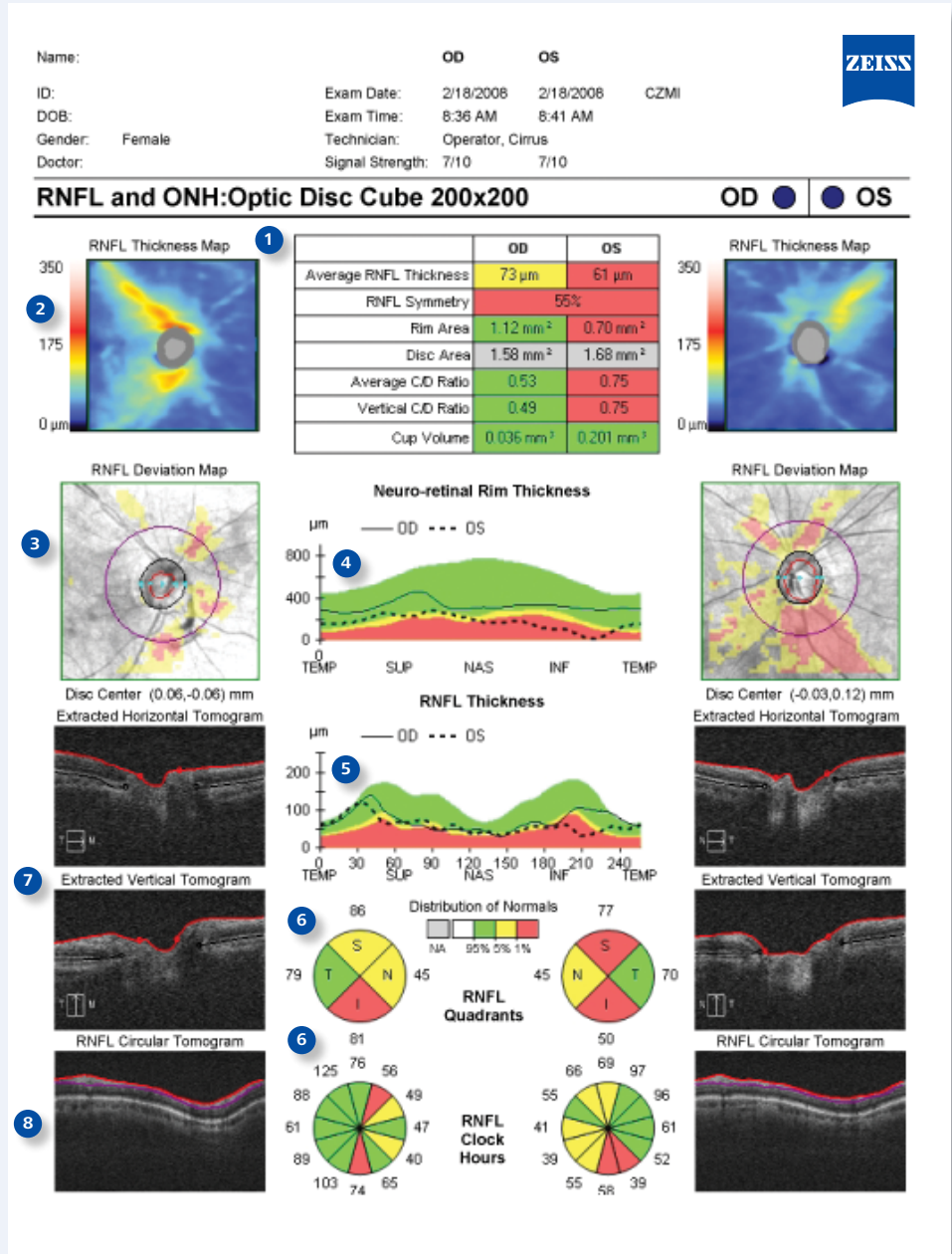
Cirrus HD-OCT analysis printouts offer clinically relevant qualitative and quantitative information in an easy-to-read format. Analysis results can be printed, viewed via review software, or integrated with other instrument data through the FORUM® Eye Care data management system. This guide explains the various areas of each printout and the valuable information it provides for your clinical assessment.

Learn more about Cirrus, log on to www.meditec.zeiss.com/cirrus

Cirrus™ HD-OCT RNFL and ONH Analysis Report

Based on the 6 mm x 6 mm data cube captured by the Optic Disc Cube 200x200 scan, this report shows assessment of RNFL and ONH for both eyes.

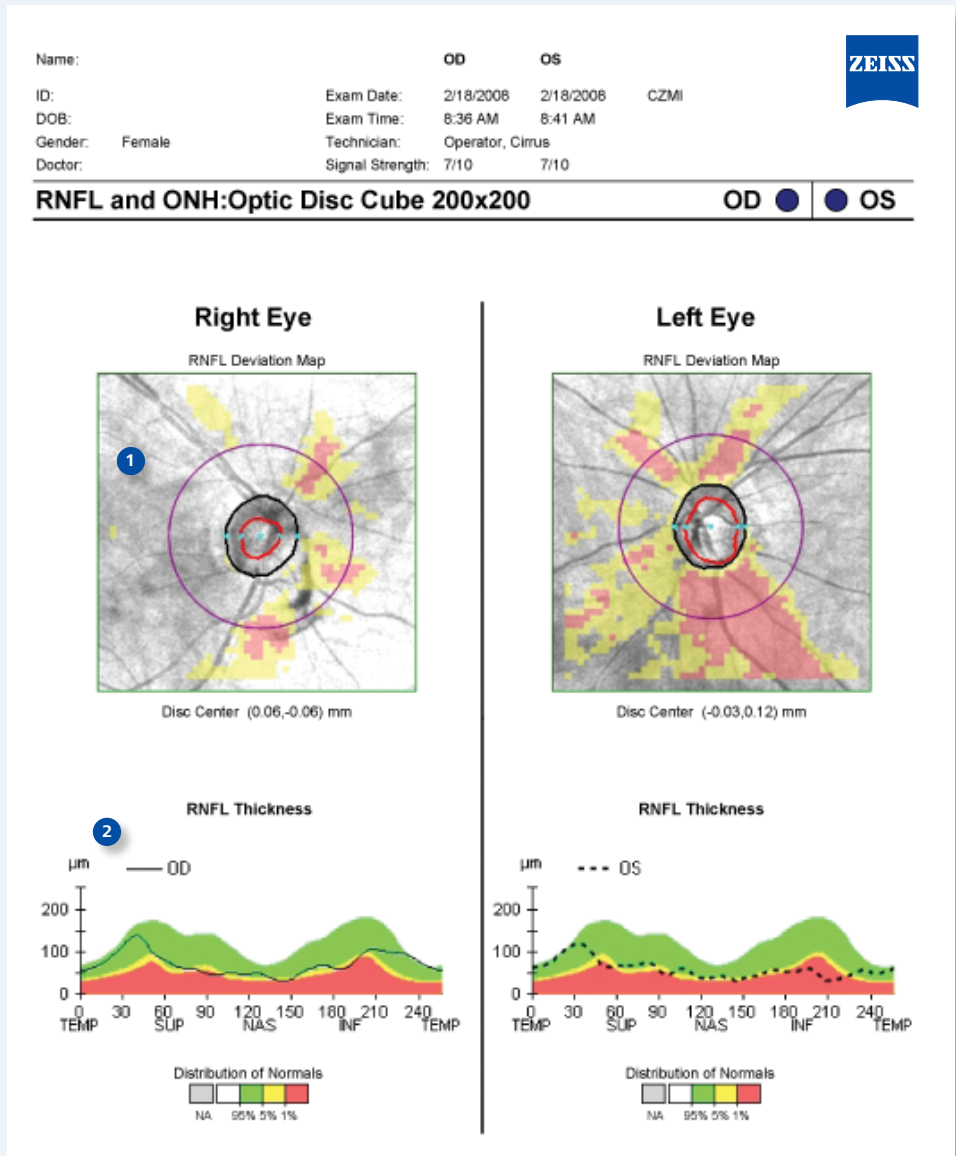
- 1 **Key parameters**, compared to normative data, are displayed in table format.
- 2 **Nerve Fiber Layer (RNFL) thickness map** is a topographical display of RNFL. An hourglass shape of yellow and red colors is typical of normal eyes.
- 3 **The RNFL Deviation Map** shows deviation from normal. OCT *en face* fundus image shows boundaries of the cup and disc and the RNFL calculation circle.
- 4 **Neuro-retinal Rim Thickness profile** is matched to normative data.
- 5 **RNFL TSNIT graph** displays patient's RNFL measurement along the calculation circle, compared to normative data.
- 6 **RNFL Quadrant and Clock Hour** average thickness is matched to normative data.
- 7 **Horizontal and vertical B-scans** are extracted from the data cube through the center of the disc. RPE layer and disc boundaries are shown in black. ILM and cup boundaries are shown in red.
- 8 **RNFL calculation circle** is extracted from the data cube, and automatically centered on the optic disc. Boundaries of the RNFL layer segmentation are illustrated.



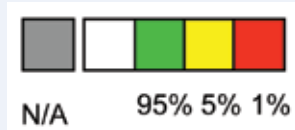
RNFL and ONH Analysis Report

Optional Patient Education Page

- OCT fundus image** with deviation map facilitates discussion with patient.
- RNFL peripapillary thickness** profile is shown for each eye, providing easier visualization and comprehension.



Distribution of Normals



Color coded indication of normative data comparison for RNFL and ONH.

Distribution of Normals:

The thickest 5% of measurements fall in the white area.

90% of measurements fall in the green area.

The thinnest 5% of measurements fall in the yellow area or below.

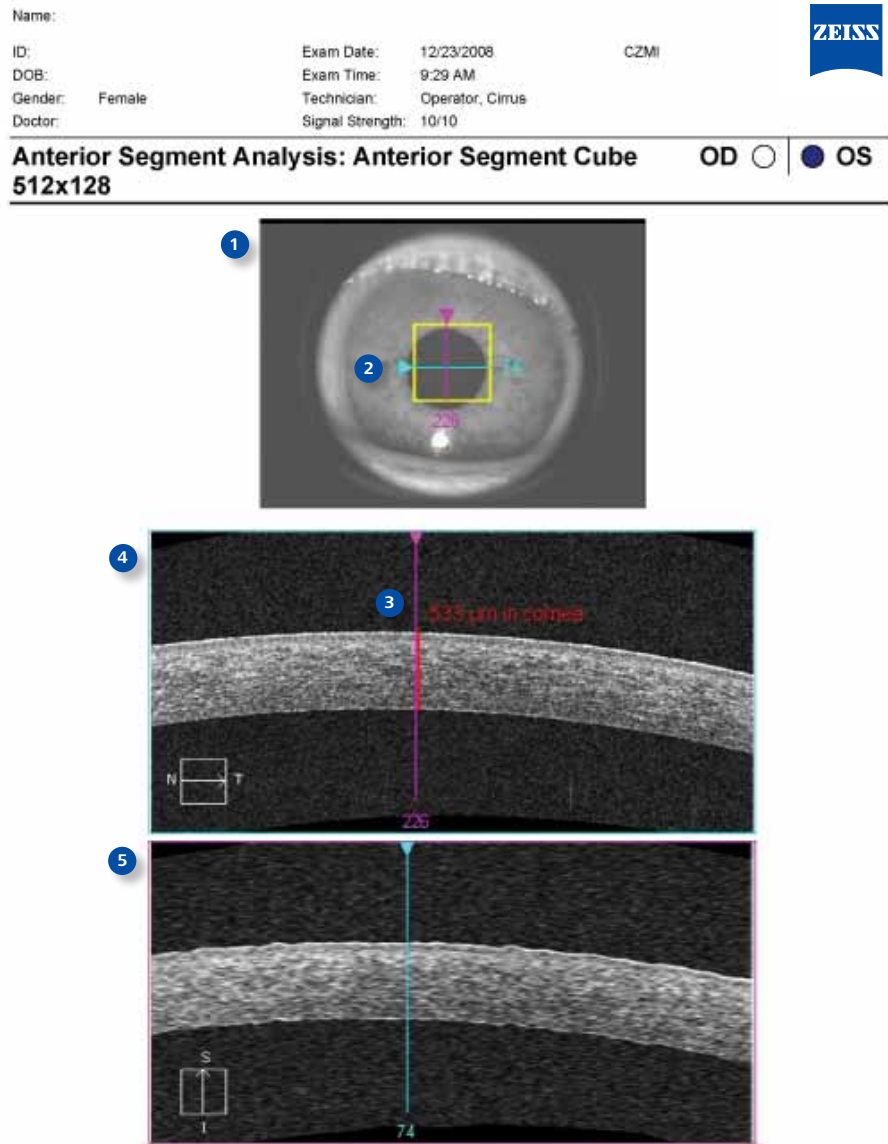
The thinnest 1% of measurements fall in the red area. Measurements in red are considered outside normal limits.

ONH values will be shown in gray when the disc area does not match with normative data.

Cirrus™ HD-OCT Anterior Segment Cube

Based on the 4 mm x 4 mm data cube captured by the Anterior Segment Cube 512x128 scan, this analysis provides qualitative and quantitative evaluation of the cornea, including visualization of pathology and measurement of central corneal thickness.

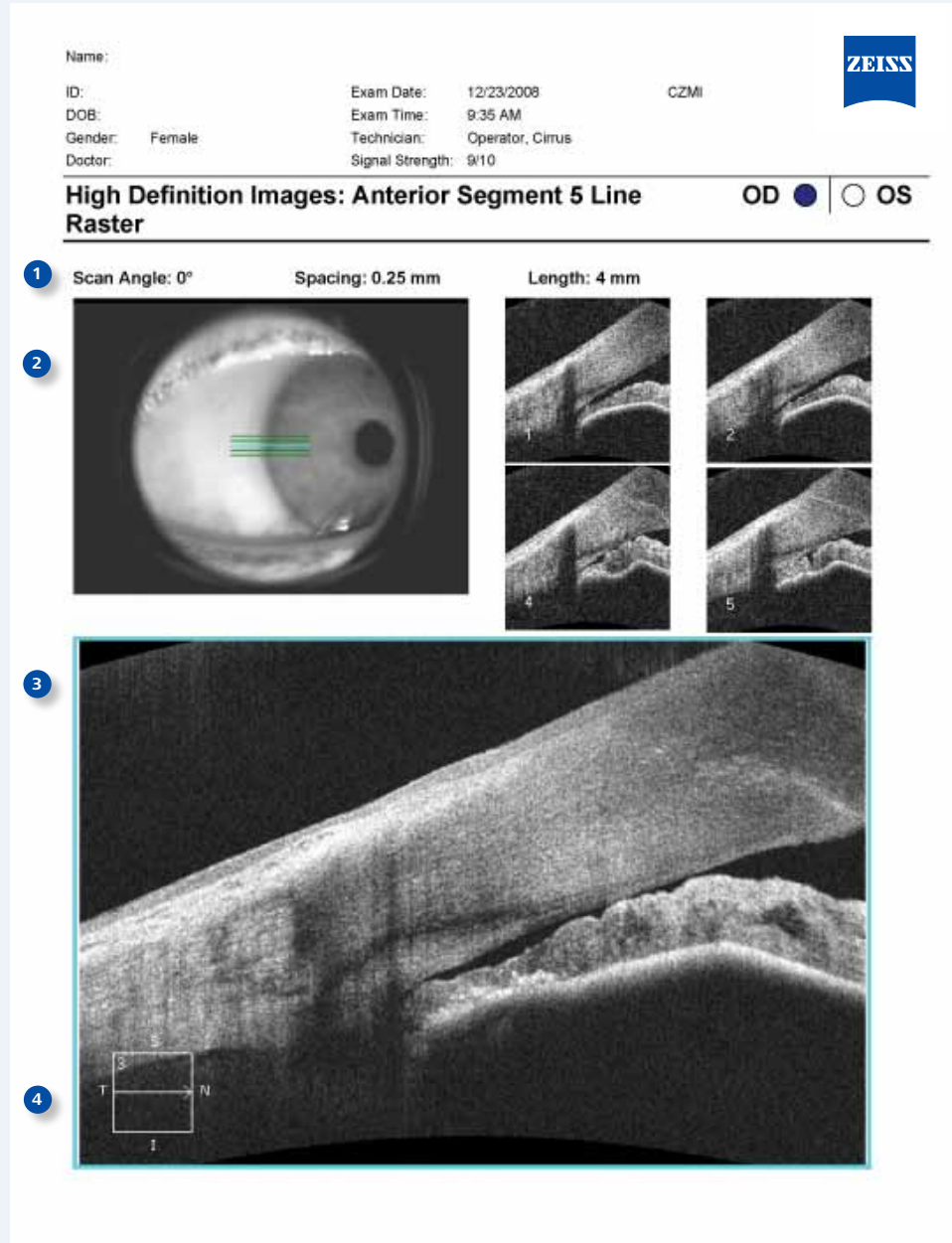
- 1 Location of the scan is shown on the iris image.
- 2 **Slide navigator** enables a simultaneous view of a selected point on the cornea image and OCT image displays.
- 3 **Central corneal thickness**, in microns, is measured with calipers.
- 4 Framed in blue, this image corresponds to the horizontal crosshair line of the fundus image above.
- 5 Framed in pink, this image corresponds to the vertical crosshair line of the fundus image above.



Cirrus™ HD-OCT Anterior Segment 5 Line Raster

The Anterior Segment 5 Line Raster is used for the assessment and documentation of the cornea and irido-corneal angle.

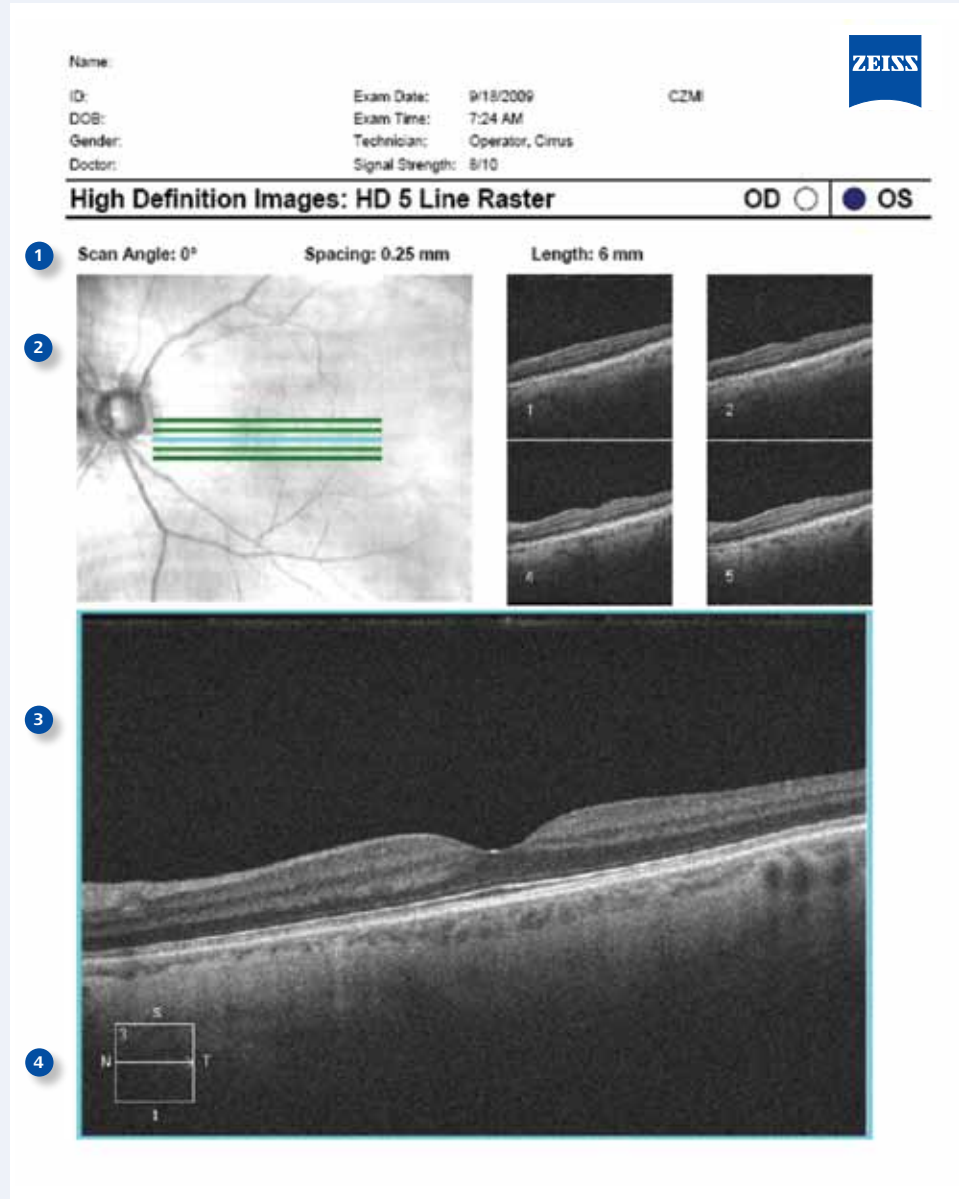
- 1 Scan angle, spacing, and length are adjustable. Parameters for the scan are indicated.
- 2 Location of scan lines is shown on the iris image.
- 3 The enlarged image corresponds with the location of the blue line on iris image above. The default is the center (third) scan of the five.
- 4 Legend on each scan image indicates which of the 5 scan lines is displayed.



Cirrus™ HD-OCT Enhanced HD Raster Report

The Enhanced HD 5 Line Raster scan protocol collects more data per scan location than the other Cirrus scans, and proprietary Selective Pixel Profiling™ evaluates all of the pixel data to construct the best possible image.

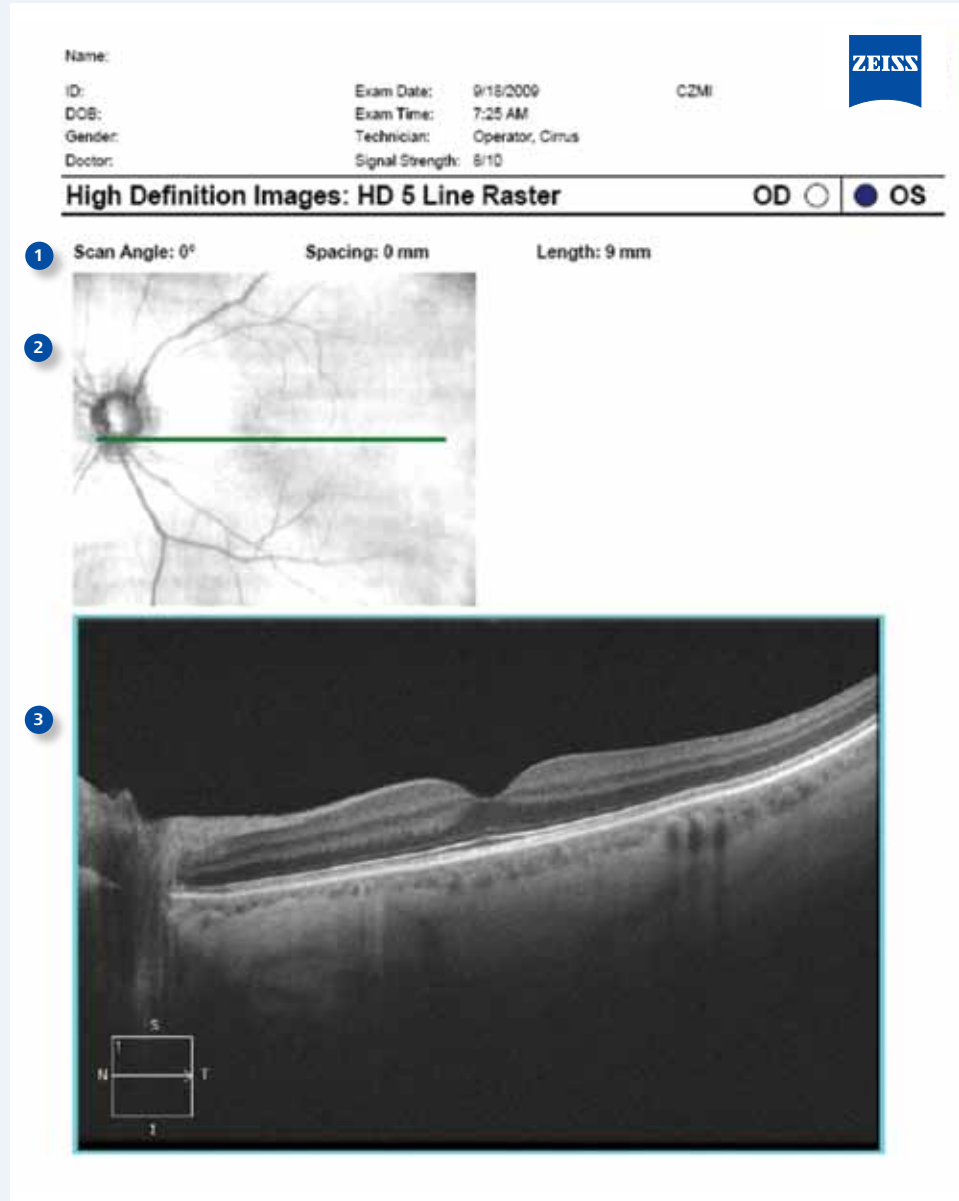
- 1 Scan angle, spacing, and length are adjustable. Parameters for the scan are indicated.
- 2 Location of scan lines is shown on the **LSO fundus image**.
- 3 Each of the **5 lines** is scanned 4 times and, with **Selective Pixel Profiling**, the optimal image is displayed. The enlarged image corresponds with the location of the blue line on fundus image above. The default is the center (third) scan of the five.
- 4 Legend on each scan image indicates which of the 5 scan lines is displayed.



Cirrus™ HD-OCT Enhanced HD Raster 20x Report

The Enhanced HD 20 Line Raster scan protocol collects more data per scan location than the other Cirrus scans, and proprietary Selective Pixel Profiling™ evaluates all of the pixel data to construct the best possible image.

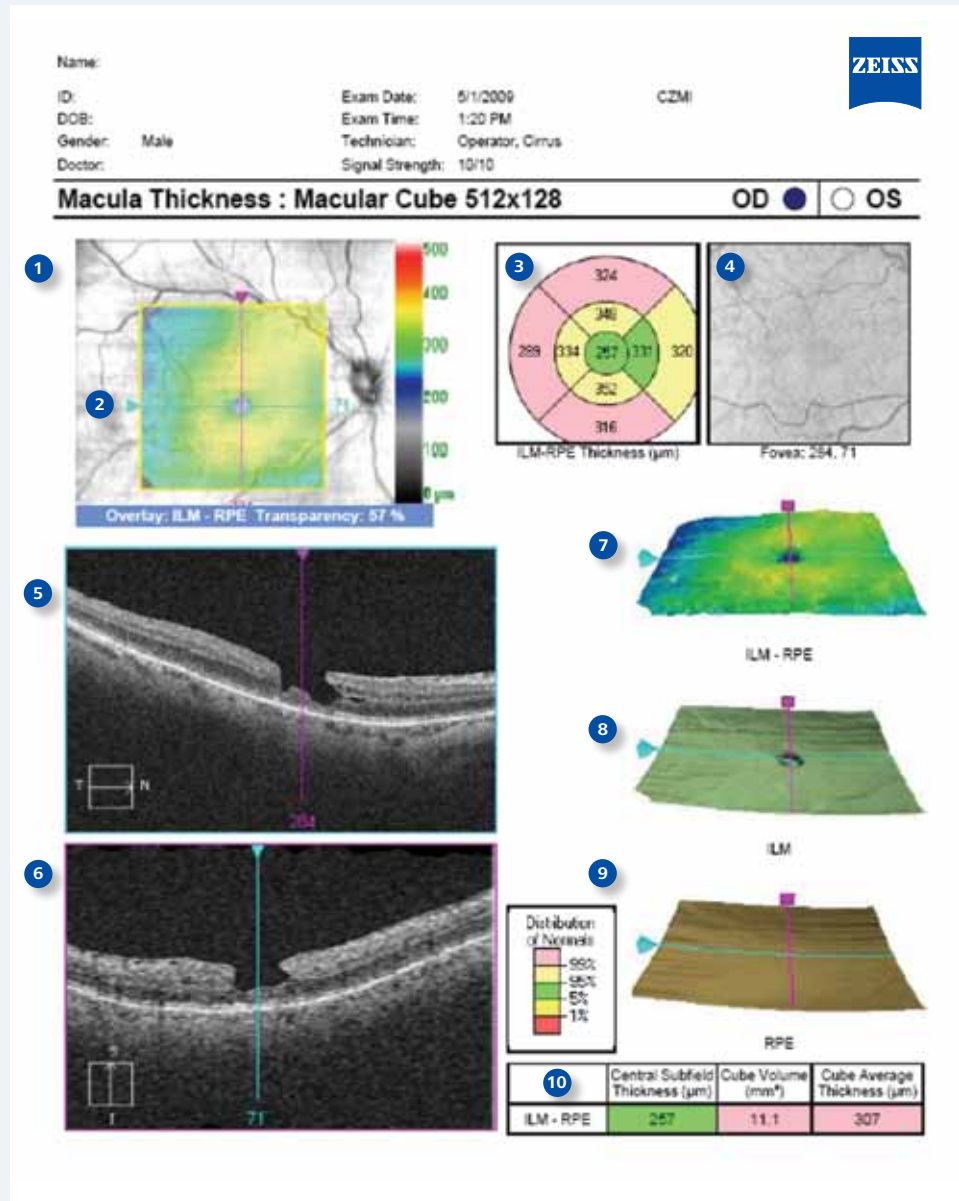
- 1 Scan angle, spacing, and length are adjustable. Parameters for the scan are indicated.
- 2 Location of scan line is shown on the **LSO fundus image**.
- 3 With 0 mm spacing, the **20 lines** of the Enhanced HD raster are collapsed into one line scanned 20 times and with **Selective Pixel Profiling**, the optimal image is displayed.



Cirrus™ HD-OCT Macular Cube Analysis Report

Based on the 6 mm x 6 mm data cube captured by the Macular Cube 512x128 or 200x200 scan, this analysis provides qualitative and quantitative evaluation of the retina.

- 1 **LSO fundus image** is shown here with a ILM-RPE retinal thickness map overlay.
- 2 **Slide navigator** enables a simultaneous view of a selected point on LSO image, OCT fundus image, retinal thickness map, layer maps, and OCT image displays.
- 3 **ETDRS grid** is automatically centered on the fovea with **Fovea Finder™**. Retinal thickness values, from ILM to RPE, in microns, are compared to normative data.
- 4 **OCT fundus image** is shown.
- 5 Framed in blue, this image corresponds to the horizontal crosshair line of the fundus image above.
- 6 Framed in pink, this image corresponds to the vertical crosshair line of the fundus image above.
- 7 **3D macular thickness map** shows retinal thickness in a topographical display.
- 8 Segmented **ILM map**.
- 9 Segmented **RPE map**.
- 10 **Macular parameters**, compared to normative data.

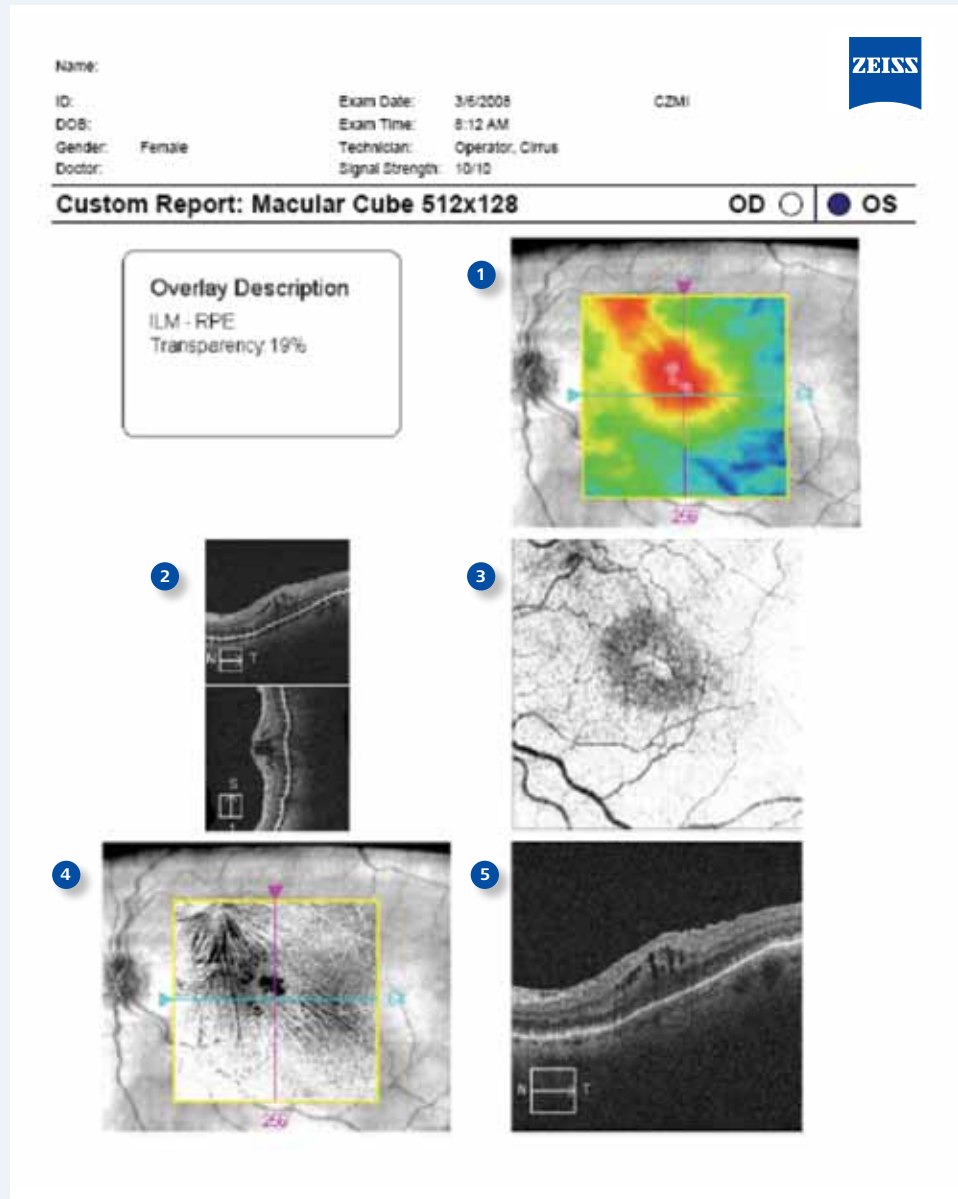


Cirrus™ HD-OCT Advanced Visualization Custom Report

From the Macular Cube 512x128 or 200x200 scan analysis, Advanced Visualization™ displays cross-sections of the image cube through three dimensions. B-scans through the X and Y axis and C-scans, or C-slabs, through the Z axis reveal unique views of the retinal tissue.

The custom print mode generates a single or multi-page report of tagged images from any Advanced Visualization analysis screen. Each selection is displayed with a description or companion image for orientation.

- 1 This **LSO fundus image** is seen with a ILM-RPE retinal thickness map overlay.
- 2 User-defined borders of the RPE slab can be seen on horizontal and vertical B-scan images.
- 3 The resulting **RPE slab image** represents an average signal intensity value for each A-scan location through the defined depth of the slab. This provides a C-scan image of the RPE.
- 4 LSO fundus image with **ILM slab overlay** reveals features of epiretinal membrane.
- 5 **B-scan image** corresponds to the horizontal crosshair line on the fundus image.



Cirrus™ HD-OCT Macular Change Analysis Report

Change analysis can be performed with Macular Cube 512x128 or 200x200 scans. Post-acquisition registration and Fovea Finder™ ensures the repeatability of thickness measurements, even in subjects with AMD, DME, VRI disorders. Data is displayed for prior and current scans.

- 1 Macular thickness over the 6 mm x 6 mm cube of data is displayed in a **topographical map** for both exams.
- 2 **Macular thickness** values are displayed for each sector of the ETDRS grid.
- 3 Placement of the cube scan is visualized on the **LSO fundus image**. The **Fovea Finder™** feature automatically centers the analysis on the fovea.
- 4 **OCT fundus image** from follow-up exam is automatically registered to baseline fundus image.
- 5 **Change analysis map** shows variance from baseline, in micrometers, and represented in color.
- 6 A **tomogram image** from the baseline scan and a precisely registered image from the current scan are viewed side by side. Simultaneous visualization of corresponding images from the two scans is possible on screen in a movie mode, or by moving the slide navigators.

