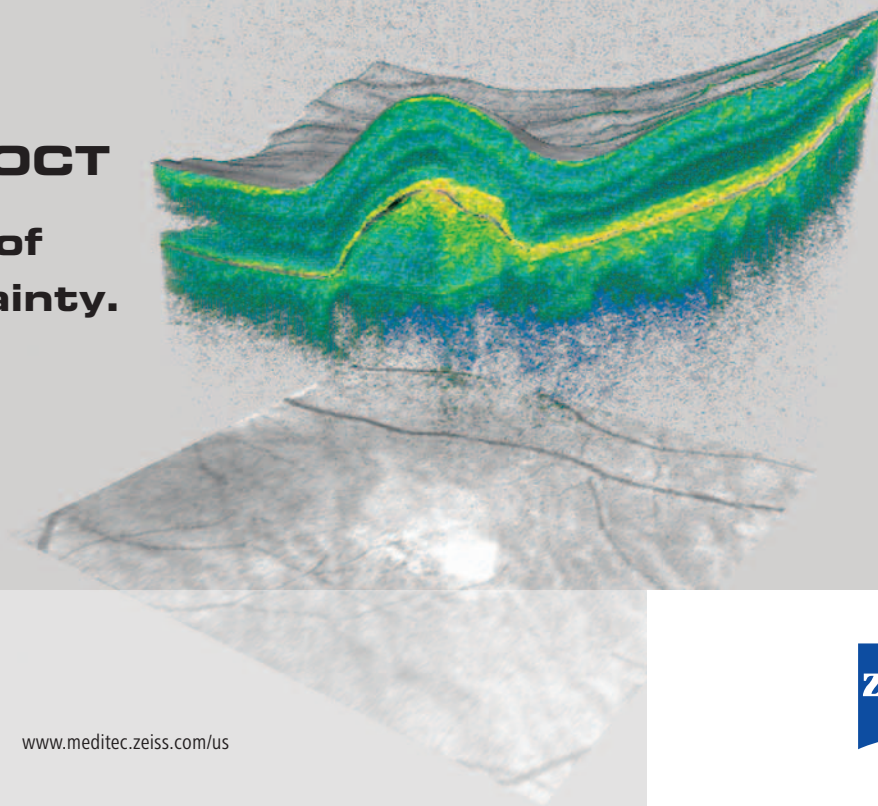
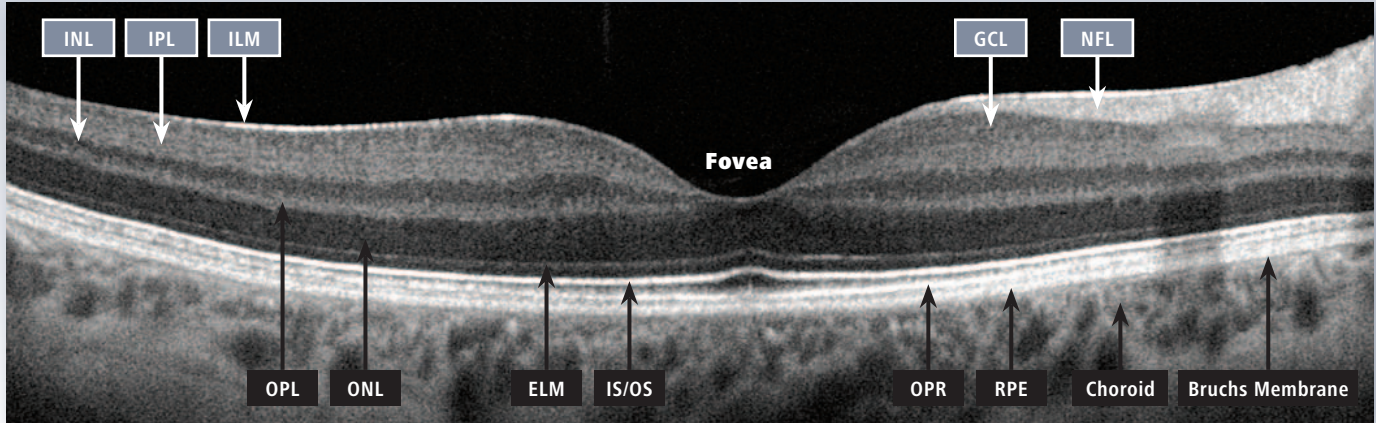


# **Cirrus HD-OCT**

**A new level of  
clinical certainty.**



## Cirrus™ HD-OCT: interpretation of retinal layers



ILM: Inner limiting membrane  
IPL: Inner plexiform layer  
INL: Inner nuclear layer  
OPL: Outer plexiform layer  
ONL: Outer nuclear layer

ELM: External limiting membrane  
IS/OS: Junction of inner and outer  
photoreceptor segments  
OPR: Outer segment PR/RPE complex

NFL: Nerve fiber layer  
GCL: Ganglion cell layer  
RPE: Retinal pigment epithelium  
+ Bruch's Membrane